



ALIGNING INTERPROFESSIONAL EDUCATION AND COLLABORATION IN PRACTICE

using promising regional experiences for international exchange

A SERIES OF (SHORT) SEPARATE VIDEOS

AP University of Applied Sciences and Arts, Antwerp, Belgium

A series of short videos was created for the case of Maria. Initially, an interview was conducted with Maria herself, followed by professionals from various disciplines sharing their perspectives on the encounter with Maria through their respective professional lenses. The following professionals will be featured: the speech therapist, the nurse, the occupational therapist, the physiotherapist, the dietitian, and the social worker. Additionally, there is a Word document providing a presentation of the case.

Authors

Ingrid Aerts, dietitian, AP University of Applied Sciences and Arts, Antwerp, Belgium

Claudia De Weerd, Physiotherapist, AP University of Applied Sciences and Arts, Antwerp, Belgium

With the INPRO consortium:

- AP University of Applied Sciences and Arts Antwerp, Belgium
- Coronaria Rehabilitation and therapy services (Coronaria Contextia Ltd), Finland
- Hanze University of Applied Sciences, Groningen, The Netherlands
- JAMK University of Applied Sciences, Jyväskylä, Finland
- Moorheilbad Harbach Gesundheits- & Rehabilitationszentrum, Austria
- Rehabilitation Centre Revalidatie Friesland, The Netherlands
- St. Poelten University of Applied Sciences, Austria

Project number: 621428-EPP-1-2020-1-NL-EPPKA2-KA Co-funded by the
Start date: Jan 1, 2021 Erasmus+ Programme
End date: Dec 31, 2023 of the European Union



Date: November 16, 2023

Creative Commons: <https://creativecommons.org/licenses/by-sa/4.0>



The European Commission's support for the production of this publication does not constitute an endorsement of the contents, which reflect the views only of the authors, and the Commission cannot be held responsible for any use which may be made of the information contained therein.

Table of Contents

Table of Contents	3
1. The Case.....	4
2. Professional View	5
2.1. Speech Therapist	7
2.2. Social Worker.....	7
2.3. Physiotherapist.....	8
2.4. Occupational therapist	8
2.5. Nurse	9
2.6. Dietitian	9
3. Use.....	10
4. ICF DISCHARGE & REFERRAL FORM.....	10

1. The Case

Person: Maria

Age at interview: 73

Brief Outline: Maria (73) was admitted to the emergency department on 14 August after a fall on the street with a rollator. She complains of pain (VAS: 5/10) in her left hip for which medical imaging was taken and it turned out to be a periprosthetic fracture on the left hip. She also has a skin tear and haematoma at the level of the left elbow and abrasion to her left knee. It is decided that a geriatric admission is necessary. Orthopaedics recommends a conservative management of the fracture, with partial support for the left leg during the first 6 weeks.

Background: Maria lives alone in a house with stairs. She has 3 children, one of whom died in 2019. She has a cleaning lady. In the house she uses a stick as walking aid, on the street this is a rollator. Climbing stairs is sometimes difficult, which is why she has installed a stairlift after her hip prostheses. She does her housework and personal care independently and has hot meals delivered to her home every day. She has a personal alarm because she has fallen in the past.

Maria already has a medical history of cardiac involvement (12/2016 subarachnoid infarction type STEMI based on subtotally occluded proximal RCA followed by successful PCI with 1 DES), hyponatremia and bilateral hip replacement. Ankle fracture, epidural infiltrates, breast carcinoma, hysterectomy.

Daily, she takes medication: Asaflow 80 mg (blood thinner) and nebivolol 5 mg and coversyl 5mg.

Parameters on admission: bp 152/79, temp 36.3, spO2: 98

MMSE: 29/30 (OT: 5/5, OR: 5/5, Inpr 3/3, Attention 5/5, GH: 3/3, Language 7/8, Constructive skills 1/1

Before her fall, she had already gone to her GP because she had lost a lot of weight recently. During her admission to hospital a tumour was discovered: a transmural invasive adenocarcinoma of the intestinal type with a moderate grade 2 differentiation.

Tumour localisation: colon ascendens, with extension on the colon side of the Bauhin's valve. Aftemas 7.5 x 5cm. The lymph nodes were tumour-free.

Medical imaging

RX of left hip: Total hip replacement, non-displaced fracture of the trochanter major, normal pubic branches and acetabulum.

X-ray pelvic face and left hip: Fracture in the base trochanter major on the left. Total hip replacement on the left.

Total hip replacement on the right.

Normal pubic branches.

RX left knee: Chondrocalcinosis lateral meniscus, Fibrosis quadriceps tendon insertion, Calcified vascular wall atomatosis. No increased intra-articular fluid. No fracture

RX thoracic face: Normal corg size. No pleural fluid or alveolar compaction. Full thickness tear supraspinatus tendon right with proximal migration caput humeri.

Please watch the videos in which Maria talks about her situation:

[INPRO Interview with Maria, the patient](#)



2. Professional View

https://www.youtube.com/playlist?list=PLhZ2yADwsg1awsF7gCXneOhwQJI_FcEAj

INPRO_Maria

Ingrid Aerts

Verborgen

7 video's 100 weergaven Laatst geüpdatet op 20 mei...

Alles afspelen Shuffle

Geen beschrijving



INPRO_Interview with Maria, the patient

Ingrid Aerts • 52 weergaven • 10 maanden geleden



INPRO_Maria_Speech Therapist

Ingrid Aerts • 10 weergaven • 10 maanden geleden



INPRO_Maria_Social worker

Ingrid Aerts • 10 weergaven • 10 maanden geleden



INPRO_Maria_Physio

Ingrid Aerts • 9 weergaven • 10 maanden geleden



INPRO_Maria_Occupational therapist

Ingrid Aerts • 9 weergaven • 10 maanden geleden



INPRO_Maria_Nurse

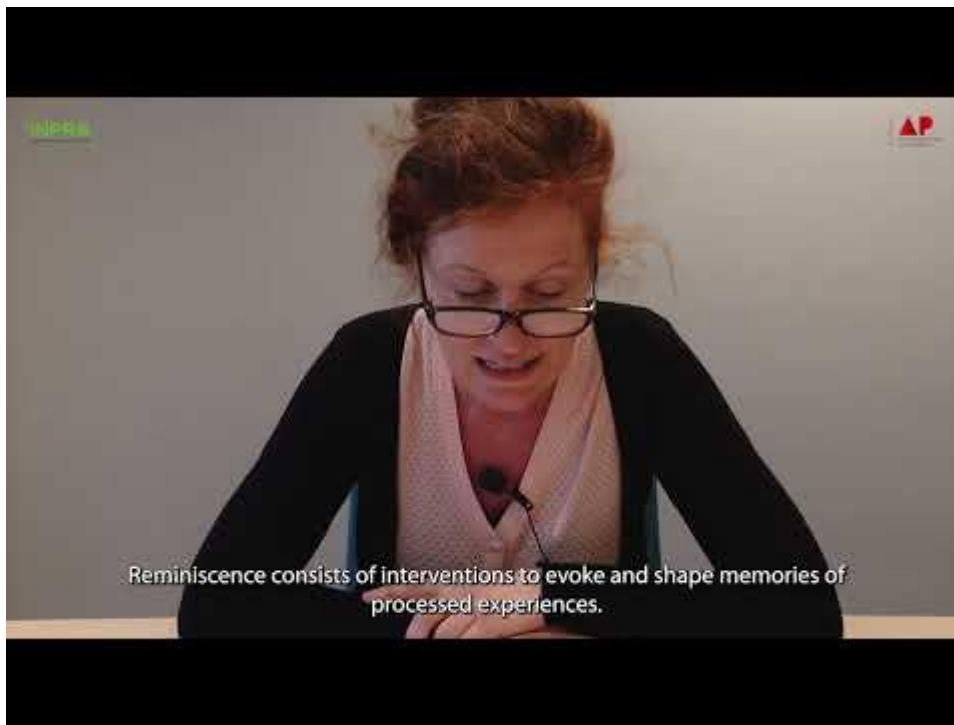
Ingrid Aerts • 6 weergaven • 10 maanden geleden



INPRO_Maria_Dietician

Ingrid Aerts • 9 weergaven • 10 maanden geleden

2.1. Speech Therapist



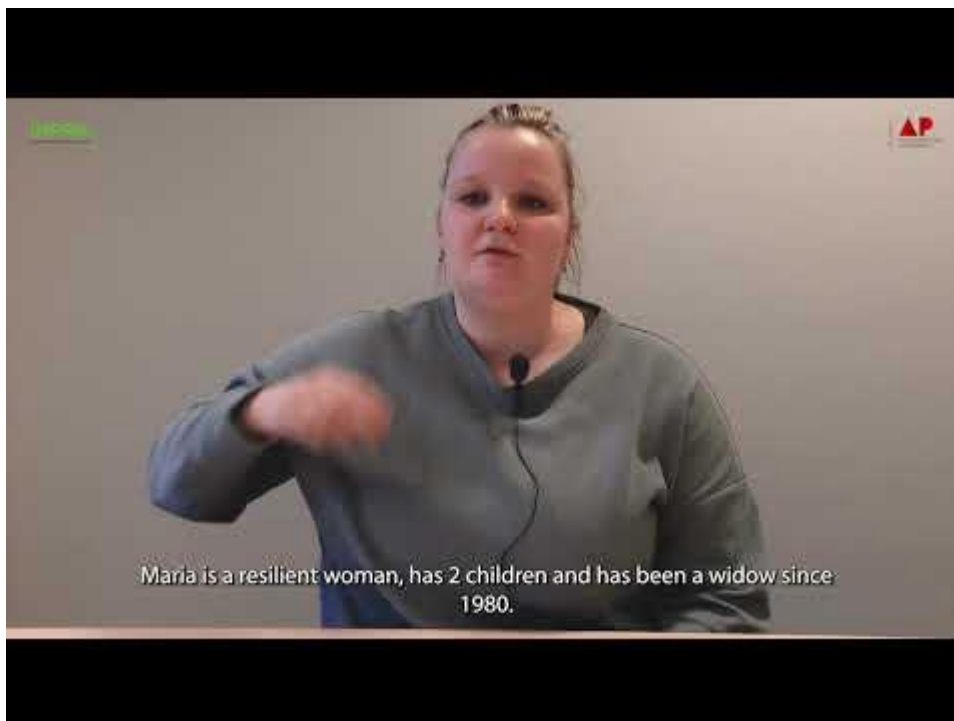2.2. Social Worker



2.3. Physiotherapist



2.4. Occupational therapist



2.5. Nurse



2.6. Dietitian



3. Use

This material can be utilized in various ways. From the professional perspectives, you can request the creation of an ICF (International Classification of Functioning, Disability and Health) framework. During an interprofessional meeting, an interprofessional care plan can be developed.

During the INPRO online intervention students had to see a movie of the patient and then the movie of his own discipline. They had to fill in all the information they could find in the Interprofessional Collaboration Form from their own professional perspective. The aim was to get to know their client and the form, so that they were prepared for the interprofessional group work. Then they had to prepare questions they need to ask the client (they will exchange on that with their group with which they will meet the client online in teams for a 20min assessment. The aim is to identify the client's health needs and to decide for an interprofessional goal (by using the ICF sheet). To make sure they are prepared when they meet their interprofessional team for the first time. In the interprofessional team they will introduce themselves with:

- In their case: what is the role of my profession?
- What are the limitations of my profession?
- Are there overlaps to other professions?

4. ICF DISCHARGE & REFERRAL FORM

[ICF DISCHARGE & REFERRAL FORM MARIA.docx](#)